

Iatrogenic pneumothorax: safety concerns when using acupuncture or dry needling in the thoracic region

Leigh McCutcheon¹, Michael Yelland²

¹School of Physiotherapy and Exercise Science, Griffith University, Gold Coast Campus, Southport, Qld, Australia, ²School of Medicine, Griffith University, Logan Campus, Meadowbrook, Qld, Australia

Background: Pneumothorax is a very rare but serious complication associated with acupuncture and dry needling around the thoracic region. Physiotherapists and other health practitioners should be aware of the risks associated with needling in this region and should take care to minimize the possibility of an iatrogenic pneumothorax.

Findings: An awareness of the signs and symptoms of a pneumothorax is necessary for practitioners using acupuncture and dry needling in the thoracic region. Understanding the normal anatomy and its variants can minimize risk associated with needling practices in this region. Various technique modifications are suggested so that the pleura or lungs are avoided while using acupuncture or dry needling in the thoracic region.

Discussion/Conclusion: Acupuncture and dry needling in this region administered by well-trained physiotherapists and other health practitioners is very safe; however, to maximize safety therapists should consider the relevant anatomy and not practise using advanced acupuncture and dry needling techniques without adequate competency-based training.

Keywords: Acupuncture, Education, Iatrogenic disease, Medical error, Pneumothorax

Background

Pneumothorax is defined as air in the pleural space. For air to enter the pleural cavity one of the following events must have occurred:¹ direct communication between the alveolar spaces and the pleura; direct or indirect communication between the atmosphere and the pleural space; or gas producing organisms are evident in the pleural space. A tension pneumothorax develops when air is trapped under a positive pressure in the pleural cavity.²

The use of acupuncture and dry needling by physiotherapists and other health practitioners is increasing internationally. Systematic reviews and clinical guidelines have highlighted the benefits of acupuncture and dry needling as part of an overall management plan for patients with various musculoskeletal disorders including low back pain, pelvic girdle pain, cervical spine pain, whiplash-associated disorder, tension type headaches, and migraines.³⁻¹⁰ Pneumothorax is a very rare but serious complication associated with acupuncture and dry needling around the thoracic region.¹¹ In particular needling to upper trapezius (GB21) and to the

thoracic erector spinae and rhomboid musculature (bladder channels) have been shown to be commonly associated with iatrogenic pneumothorax. Other regions around the thorax which pose a risk of pneumothorax include the sub-clavicular region, the supra-clavicular region, intercostal spaces, interspinal spaces, and congenital foramen associated with the sternum, the suprascapular, and infrascapular fossa. Physiotherapists and other medical practitioners should be aware of the risks associated with needling around the thorax and should take care to minimize the likelihood of inadvertently creating a pneumothorax.

Classification and aetiology of pneumothorax

Pneumothoraces are classified as spontaneous or traumatic. Spontaneous pneumothorax is labelled as primary where there is no underlying lung disease present, or secondary which is associated with pre-existing lung disease. In primary spontaneous pneumothorax, 91% of cases are smokers, with the relative risk increasing with the number of cigarettes smoked, particularly in males.^{12,13} Other risk factors for primary spontaneous pneumothorax include a tall slim body type, Marfan's syndrome, pregnancy, or a family history.^{12,14} Secondary spontaneous pneumothorax may be associated with chronic obstructive

Correspondence to: L McCutcheon, School of Physiotherapy and Exercise Science, Griffith University, Gold Coast Campus, PO Box 342, Robina, Qld 4226, Australia. Email: leighmcc@bigpond.net.au

pulmonary disease (COPD), tuberculosis, sarcoidosis, cystic fibrosis, severe asthma, idiopathic pulmonary fibrosis, malignancy, necrotising pneumonia and HIV associated *Pneumocystis carinii* pneumonia.^{1,15} Secondary spontaneous pneumothorax has also been associated with connective tissue disorders including rheumatoid arthritis (RA), ankylosing spondylitis (AS), scleroderma, systemic lupus erythematosus (SLE), polymyositis, catamenial pneumothorax and Ehlers–Danlos syndrome.^{1–2} The use of oral corticosteroids has also been associated with spontaneous pneumothorax.¹⁶

The incidence of primary spontaneous pneumothorax is 7.4–24/100 000 in men and 1.2–10/100 000 in women.^{1,13,17} Primary spontaneous pneumothorax occurs predominantly in adults in their second and third decades of life.¹² The incidence of secondary pneumothorax is 6.3/100 000 in males and 2.0/100 000 in females;¹⁷ however, in individuals with COPD the incidence increases to 26/100 000 with a 3.5-fold increase in mortality associated with secondary spontaneous pneumothorax.¹² Secondary spontaneous pneumothorax has been shown to peak in incidence in the 60- to 65-year age bracket.¹²

Traumatic pneumothorax may be iatrogenic or non-iatrogenic. Causes of non-iatrogenic pneumothorax include penetrating or non-penetrating traumatic injuries, rib fractures, and high risk professions or sports including diving or flying. The common causes of iatrogenic pneumothorax include transthoracic needle biopsy, central venous subclavian vein catheterization, thoracentesis, transbronchial lung biopsy, pleural biopsy, intercostal nerve block, suprascapular nerve block, tracheostomy, nasogastric feeding tube placement, nephrectomy, gastrostomy, cardiopulmonary resuscitation, and positive pressure ventilation.^{1,18–20} Iatrogenic pneumothorax has also been reported to occur with medical research utilizing electromyography fine wiring to assess activation of muscles including levator scapulae, trapezius, serratus anterior, rhomboids, the diaphragm, cervical and thoracic paraspinal muscles, intercostals, pectoralis major and minor, supraspinatus, infraspinatus, and subscapularis.^{21–23} Similarly injections of prolotherapy solutions, botulinum toxin, anaesthetic, or cortisone into ligaments and muscles in the thoracic region have been associated with iatrogenic pneumothoraces.^{21,24,25}

Acupuncture- and Dry Needling-induced Iatrogenic Pneumothorax

Incidence

Acupuncture and dry needling has been identified as an additional cause of iatrogenic pneumothorax.²⁶ The incidence of acupuncture-induced pneumothorax is less than 1/10 000,^{27,28} which is classed as very rare by the WHO classification.²⁹ There have however been in excess of 100 case reports of iatrogenic

pneumothorax due to acupuncture and dry needling reported in the research literature, including four cases of death.^{25,27,28,30–34} Most iatrogenic pneumothoraces associated with acupuncture and dry needling are unilateral, although case studies of bilateral iatrogenic pneumothoraces have been reported.^{16,35}

Large prospective investigations into the incidence of acupuncture-induced iatrogenic pneumothorax have been conducted in the United Kingdom, Japan, Czechoslovakia, Switzerland, and Germany. During the survey of adverse events following acupuncture studies in the United Kingdom over 66 000 consultations were performed by medical practitioners and physiotherapists and there were no pneumothoraces.^{36–39} Similarly in Japan, no pneumothoraces occurred during a 6-year survey of 65 482 consultations conducted by acupuncture therapists.^{40,41} In Czechoslovakia, the incidence of acupuncture-induced iatrogenic pneumothorax was 2 in 139 988 equating to 1 in 69 994 consultations by hospital-based medical physicians.⁴² German acupuncture trials (GERAC) have been the largest prospective studies into the efficacy, effectiveness, and safety of acupuncture by well-trained medical practitioners to date. From the initial 763 900 consultations reviewed during GERAC, Melchart *et al.*⁴³ reported an incidence of 1/381 950 consultations; however, after 2 338 146 consultations, Witt *et al.*⁴⁴ reported the incidence of iatrogenic pneumothorax to be 1/1 170 000. The programme for evaluation of patient care with acupuncture (PEP-Ac) provided further analysis of the GERAC trials, summing that in over 4 000 000 acupuncture consultations by medical practitioners three pneumothoraces occurred equating to a risk of 1/1 300 000 consultations.^{45,46} However not all of the consultations included in the above cited prospective studies involved needling in the thoracic region. It is important to establish if a pneumothorax is spontaneous or iatrogenic because with primary spontaneous pneumothorax, the risk of recurrent pneumothorax is increased while with iatrogenic pneumothorax this risk is not increased.¹⁷

Clinical features

A good working knowledge of the clinical features of pneumothorax is vital to physiotherapists and other health practitioners practising acupuncture or dry needling in and around the thoracic region. This facilitates its early recognition and may improve the information and consent processes for these procedures. It also aids the diagnosis of spontaneous pneumothorax masquerading as a thoracic musculoskeletal condition in patients with thoracic region pain presenting for acupuncture or manual therapy.

Such presentations are well described in the physical therapy literature.^{31,47,48}

The signs and symptoms of a pneumothorax may include dyspnoea (shortness of breath) on exertion, tachypnoea (increased respiratory rate), chest pain, dry cough, cyanosis, diaphoresis (sudomotor activity), and decreased breath sounds on auscultation over the affected region.^{49,50} In rare circumstances a tension pneumothorax, which is life threatening due to displacement of mediastinal structures and resultant compromised cardiopulmonary function, may develop.⁵⁰

The symptoms of acupuncture-induced iatrogenic pneumothorax commonly do not occur until after the treatment session, sometimes taking several hours to develop. Patients need to be cautioned as to the possible symptoms of pneumothorax and what to do in the event of such symptoms. Therapists should consider if the patient has a pre-existing lung condition or any other risk factors predisposing them to spontaneous pneumothorax and thereby iatrogenic pneumothorax. Another consideration may be if the patient is going to be exposed to barometric stress, such as flying or scuba diving.

In the event of a suspected pneumothorax, either on presentation or following acupuncture or dry needling, chest percussion and auscultation may reveal hyper-resonance and decreased air entry. A plain chest X-ray should be performed if such signs are found, or indeed if any uncertainty about the diagnosis of pneumothorax remains as the diagnostic validity of percussion and auscultation in detecting pneumothorax is limited.⁵⁰ Prompt referral for medical management is indicated should a pneumothorax be found. Degrees of lung collapse have been graded as mild (<20%), moderate (20–40%), and severe (>40%).⁵¹ In otherwise healthy patients with mild iatrogenic pneumothorax monitoring as either an inpatient or an outpatient, is usually sufficient to ensure that the lung re-inflates without incident.¹⁷ Oxygen saturation levels should be considered and oxygen administered as necessary.⁴⁹ Should a larger moderate to severe pneumothorax or a tension pneumothorax develop a chest drain (pigtail catheter or tube thoracostomy) will usually be utilized over a period of days as re-expansion of the lung is achieved.

Anatomical considerations

Consideration of the relevant anatomy by adequately trained practitioners will further reduce the risk of an iatrogenic pneumothorax. The primary areas associated with acupuncture- or dry needling-induced pneumothorax are the regions of thorax including the upper trapezius, paraspinal, medial scapular, and subclavicular regions.^{16,17,26,27,31,35,48,52–56} Anatomically the lung

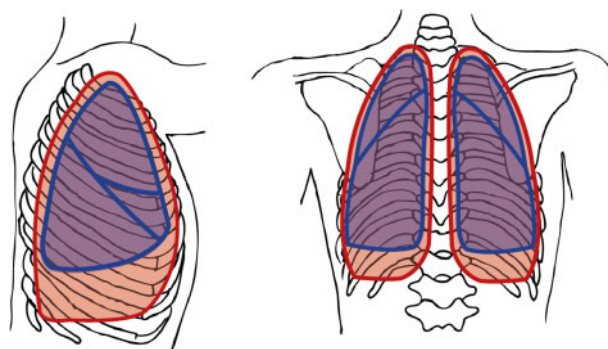


Figure 1 Right lateral view and posterior view of lungs and pleural lining relative to skeletal structures in the thoracic region.

fields extend to the sixth rib anteriorly at the mid-clavicular line, to the eighth rib laterally at the mid-axillary line and to the tenth rib posteriorly. The pleura extends a further two ribs below each of these levels (Fig. 1). This is particularly important to note posteriorly where at the lateral border of the erector spinae the pleura extends down to the twelfth rib and care should be taken when needling iliocostalis or the outer bladder channel.

The apex of the lung extends 2–3 cm above the clavicular line and care should be taken when needling upper trapezius or GB21. In individuals who smoke, additional care should be taken when needling cephalad to the first rib or in the supraclavicular region to avoid puncturing a bulla (a sharply bordered region in emphysematous lung with a diameter of less than 1 cm and a thickness of less than 1 mm) or a bleb (an air-filled cavity of the pulmonary pleura) formation which occur predominantly in the apex of the lung.^{1,48}

There are three areas in the thorax with congenital anomalies of relevance to acupuncture and dry needling regions. Congenital foramina in the infraspinous fossa of the scapula with diameters up to 2–5 mm have been described in 0.8–5.4% of individuals.^{57,58} Such foramina have also been described in the supraspinous fossa. In 5–8% of individuals a congenital foramina exists due to incomplete ossification and fusion of the sternal plates which most commonly occur at the level of the fourth intercostals plate.^{59–61} A congenital sternal foramen is usually not able to be palpated due to overlying muscle tendon fibres and connective tissue.⁵⁹ It is, however, more likely that cardiac tamponade due to injury of the heart or pericardium could occur if needling was performed deeper than 13–25 mm directly over the sternum.⁶² Consequently physiotherapists are advised to needle superficially in an oblique cephalad direction when performing acupuncture or dry needling over the sternum.

Vulnerable areas in the thoracic region

Based on post-mortem examinations, Peuker *et al.* concluded that needle puncture depths of 10–20 mm

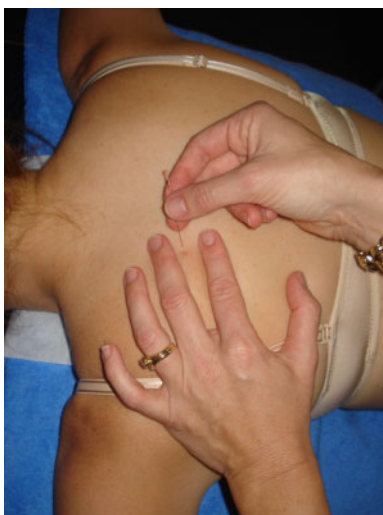

Figure 2 Needling directly over the fourth rib using an acute angle of penetration and straddling the rib with two fingers.

parasternally or in the region of the mid-clavicular line could result in a pneumothorax.^{28,48,59} Posteriorly, the surface of the lungs is 15–20 mm beneath the dermal surface in the parascapular zone.^{28,59} Case studies have been reported describing iatrogenic pneumothoraces from needling of ST11 and ST12 in the supraclavicular region and LU2, ST2, and KI27 in the infraclavicular region; KI22 and KI27 parasternally, ST12 to ST18 in the mid-clavicular line, and BL41 to BL50, rhomboids, serratus posterior superior, levator scapulae, splenius cervicis, longissimus thoracis, iliocostalis thoracis, semispinalis thoracis, cervicis and capitis in the medial scapular region.^{16,17,27,28,35,52,54,55}

When needling around the thoracic region the risks and benefits of maintaining site specificity should be considered. Numerous clinical trials and recent brain imaging studies have revealed that there is no significant difference between needling directly onto an acupuncture point compared with sham needling at a point which is a marginal distance from an actual acupuncture point.^{63,64} Hence needling points which lie directly over intercostal spaces should be avoided^{56,65} as potential benefits do not outweigh the risks. It is safer to straddle a rib with two fingers and needle directly over the rib at an acutely oblique angle (Fig. 2). Alternative safer techniques include more superficial forms of dermal needling, such as Baldry dry needling or Japanese acupuncture, using acupuncture needles of a shorter length.

Reducing the risk of iatrogenic pneumothorax

While iatrogenic pneumothorax is a very rare adverse event in association with acupuncture and dry needling³⁸ and virtually all pneumothoraces fully resolve and mortality is extremely remote, due care to prevent a pneumothorax occurring should always be observed. Additional care should be taken when dry needling or acupuncturing shoulder muscles that

have been associated with fine wire electromyography-induced iatrogenic pneumothoraces or acupuncture-induced pneumothoraces such as subscapularis, supraspinatus, infraspinatus, levator scapulae, pectoralis major and minor.^{21–23,25,65} Due to the possibility of a congenital foramen in the supraspinous or infraspinous fossa acupuncture and dry needling in this region should be directed at an oblique angle along the fossa towards the glenohumeral joint. When dry needling pectoralis major needling may be performed via a pincer grip hold in the anterior axillary region, gripping the pectoralis major between thumb and fingers, and needling performed across the fibres of the muscle. Dry needling of pectoralis minor may be performed by needling obliquely towards the coracoid process. Dry needling of the origin of levator scapulae may be performed safely if the patient’s scapula is able to wing off the chest wall by lying the patient on the ipsilateral side and elevating the arm or alternatively if the patient lies on their contralateral side with their ipsilateral arm held behind their back (Fig. 3). Due to the risk of pneumothorax, it is advisable not to attempt to needle the origin of levator scapulae if the medial border of the scapulae is not able to wing off the chest wall.

Dry needling muscles on the lateral chest wall including serratus anterior and latissimus dorsi or acupuncture points in the mid-axillary line including SP17 to SP21, GB21, and GB22 also need to be considered to increase safety. Once again the technique of straddling a rib with two fingers and needling directly over the rib at an acutely oblique angle should be utilized. Latissimus dorsi can be dry needled safely by using a pincer grip hold and needling across the fibres as the muscle is lifted off the chest wall.

Needling of GB21 and particularly upper trapezius trigger points has been associated with iatrogenic pneumothorax.^{26,35,53,55} When needling upper trapezius or GB21 with the patient in a prone position, the bulk of upper trapezius is lifted in a cephalad direction using a broad pincer grip. While holding the muscle bulk the physiotherapist should attempt to lay the thumb of their non-needling hand that is holding the muscle bulk along the line of the first rib. Maintaining the position of the thumb, the upper trapezius is needled in a cephalad direction cephalad of the thumb. If a pecking style of dry needling is being utilized, the physiotherapist should ensure that the needle does not move in a caudad direction. If the acupuncture needle is being left *in situ*, its cephalad direction should be monitored to decrease the risk of upper trapezius grabbing the needle and drawing it towards the apex of the lung. Arm position should also be considered. The patient’s arms may be down

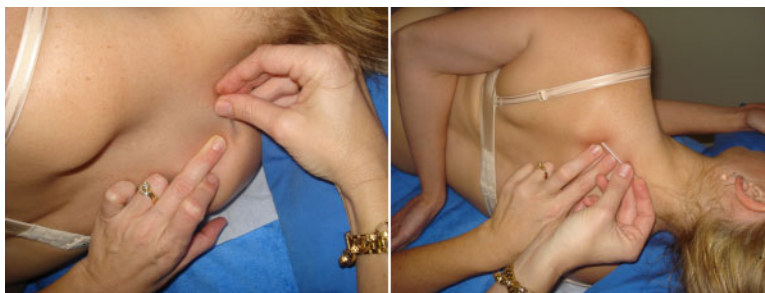


Figure 3 Needling levator scapulae by winging the scapula off the chest wall in side lying with the ipsilateral arm elevated or alternatively the patient lies on their contralateral side with their ipsilateral arm held behind their back. Note: Do not attempt to needle the origin of levator scapulae if the medial border of the scapulae is not able to wing off the chest wall.

by their side, hanging over the side of the bed or elevated onto the bed next to the patient's head. If the acupuncture needle is left *in situ*, the patient should be advised that they can only move their arms upwards towards a flexed shoulder position if they need to change the position of their arms as this assures that the needle angle will not change to point in a caudad direction (Fig. 4).

Acupuncture Training and Continuing Education

Prospective studies and retrospective surveys have determined that acupuncture and dry needling is very safe in the hands of competent practitioners who have completed adequate training programs.³⁸ It has been suggested that adequate competency-based training with regard to safety in acupuncture and dry needling minimizes foreseen adverse events.^{11,28,66} Educational levels and continuing professional development requirements are currently the subject of intense debate;⁶⁶ however, case study reviews involving needle penetration to pleura or pericardium suggest that poor practitioner judgment in terms of needle depth penetration, needling technique, and relevant anatomical knowledge is at times linked to iatrogenic pneumothorax.^{37,62} Clinical regulatory bodies should uphold professional standards and reinforce continued professional development requirements for needling vulnerable areas with such standards affecting qualified practitioners, educational bodies, and professional organizations.

Summary

The risks associated with the use of acupuncture and dry needling in the thoracic region warrant consideration in view of the growing number of physiotherapists and other health practitioners globally using these techniques. Extra care should be taken when needling patients with conditions or risk factors that have been associated with primary or secondary spontaneous pneumothorax such as COPD, lung cancer, RA, AS, SLE, sarcoidosis, Marfan's syndrome, a tall slim build, cortisone therapy, or in smokers. Any presenting signs and symptoms of a primary or secondary pneumothorax should alert the practitioner who is considering treating a patient to assess further with chest auscultation, percussion, and X-ray and referral for urgent medical management if indicated.

Iatrogenic pneumothorax relating to acupuncture or dry needling is very rare and the risk of related mortality is extremely remote. Safer techniques include needling dermally or in an acutely oblique direction over bony skeletal structures, or where possible lifting the muscle and soft tissue to be needled away from the chest wall and needling away from the underlying lung tissue. Acupuncture and dry needling administered by well-trained physiotherapists and other medical practitioners is very safe; however, to maximize safety, therapists should not perform advanced acupuncture and dry needling techniques in vulnerable areas, such as the thoracic

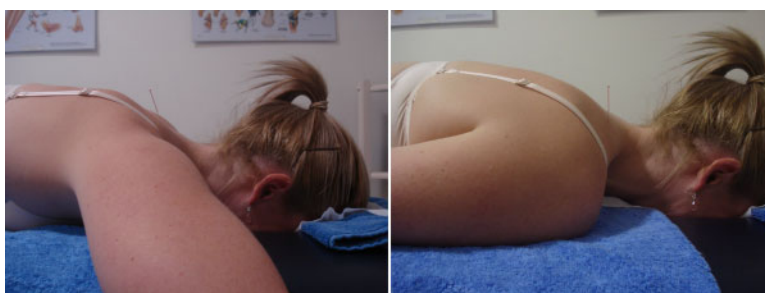


Figure 4 Angle of inclination alters with arm position when the needle is left *in situ* in upper trapezius (Gall Bladder 21). A degree of cephalad obliquity should be maintained at all times and patients should be advised that they can alter their arm position only by elevating their arms.

region, without completing adequate training by recognized educational bodies.

References

- 1 Noppen M, De Keukeleire T. Pneumothorax. *Respiration* 2008;**76**:121–7.
- 2 Sahn SA, Heffner JE. Spontaneous pneumothorax. *N Engl J Med* 2000;**342**:868–74.
- 3 Gross A, Miller J, D’Sylva J, Burnie SJ, Goldsmith CH, Graham N, *et al*. Manipulation or mobilisation for neck pain. *Cochrane Database Syst Rev* 2010;(1):CD004249.
- 4 Linde K, Allais G, Brinkhaus B, Manheimer E, Vickers A, White AR. Acupuncture for migraine prophylaxis. *Cochrane Database Syst Rev* 2009;(1):CD001218.
- 5 Linde K, Allais G, Brinkhaus B, Manheimer E, Vickers A, White AR. Acupuncture for tension-type headache. *Cochrane Database Syst Rev* 2009;(1):CD007587.
- 6 Trinh KV, Graham N, Gross AR, Goldsmith CH, Wang E, Cameron ID, *et al*. Acupuncture for neck disorders. *Cochrane Database Syst Rev* 2006;(3):CD004870.
- 7 Guzman J, Haldeman S, Carroll LJ, Carragee EJ, Hurwitz EL, Peloso P, *et al*. Clinical practice implications of the Bone and Joint Decade 2000–2010 Task Force on Neck Pain and Its Associated Disorders: from concepts and findings to recommendations. *Spine (Phila Pa 1976)* 2008;**33**(4 Suppl):S199–213.
- 8 Vleeming A, Albert HB, Ostgaard HC, Sturesson B, Stuge B. European guidelines for the diagnosis and treatment of pelvic girdle pain. *Eur Spine J* 2008;**17**:794–819.
- 9 Low back pain: early management of persistent non-specific low back pain NICE clinical guideline. London: Excellence NIfHaC; 2009.
- 10 Guidelines for the management of acute whiplash-associated disorders for health professionals. Sydney: Authority NMA; 2007.
- 11 Bensoussan A, Myers SP, Carlton AL. Risks associated with the practice of traditional Chinese medicine: an Australian study. *Arch Fam Med* 2000;**9**:1071–8.
- 12 Bascom R, Benninghoff MG, Alam S. Pneumothorax. 2009. Available from: <http://emedicine.medscape.com/article/424547-overview>.
- 13 Wakai A. Spontaneous pneumothorax. *Clin Evid (Online)* 2008;**2008**:1505.
- 14 Chiu HT, Garcia CK. Familial spontaneous pneumothorax. *Curr Opin Pulm Med* 2006;**12**:268–72.
- 15 de Lassence A, Timsit JF, Tafflet M, Azoulay E, Jamali S, Vincent F, *et al*. Pneumothorax in the intensive care unit: incidence, risk factors, and outcome. *Anesthesiology* 2006;**104**:5–13.
- 16 Su JW, Lim CH, Chua YL. Bilateral pneumothoraces as a complication of acupuncture. *Singapore Med J* 2007;**48**:e32–3.
- 17 Chauffé RJ, Duskin AL. Pneumothorax secondary to acupuncture therapy. *South Med J* 2006;**99**:1297–9.
- 18 Sanchez HB, Mariano ER, Abrams R, Meunier M. Pneumothorax following infraclavicular brachial plexus block for hand surgery. *Orthopedics* 2008;**31**:709.
- 19 Zhan C, Smith M, Stryer D. Accidental iatrogenic pneumothorax in hospitalized patients. *Med Care* 2006;**44**:182–6.
- 20 Despars JA, sasson CSH, Light R. Significance of iatrogenic pneumothoraces. *Chest* 1994;**105**:1147–51.
- 21 Chiou-Tan FY, Miller JS, Goktepe AS, Zhang H, Taber KH. Sectional neuroanatomy of the upper thoracic spine and chest. *J Comput Assist Tomogr* 2005;**29**:281–5.
- 22 Miller JS, Goktepe AS, Chiou-Tan F, Zhang H, Taber KH. Sectional neuroanatomy of the middle thoracic spine (t5–t8) and chest. *J Comput Assist Tomogr* 2006;**30**:161–4.
- 23 Al-Shekhlee A, Shapiro BE, Preston DC. Iatrogenic complications and risks of nerve conduction studies and needle electromyography. *Muscle Nerve* 2003;**27**:517–26.
- 24 Dorman T. Prolotherapy: a survey. *J Orthop Med* 1993;**15**:49–50.
- 25 Miller JS, Chiou-Tan F, Zhang H, Taber KH. Sectional neuroanatomy of the lower thoracic spine and chest. *J Comput Assist Tomogr* 2007;**31**:160–4.
- 26 Shafer N. Pneumothorax following ‘trigger point’ injection. *JAMA* 1970;**213**:1193.

- 27 Juss JC, Speed CA, Warrington J, Mahadeva R. Acupuncture induced pneumothorax – a case report. *Acupunct Med* 2008;**26**:193–6.
- 28 Peuker ET, White A, Ernst E, Pera F, Filler TJ. Traumatic complications of acupuncture. Therapists need to know human anatomy. *Arch Fam Med* 1999;**8**:553–8.
- 29 Organisation WH. Adverse events following immunisation (AEFI): causality assessment. 2010. Available from: http://www.who.int/immunisation_safety/en/.
- 30 Ritcher JC, Kamalt W, O’Connor P. Pneumothorax and pleural empyema after acupuncture. *Intern Med J* 2008;**38**:678–80.
- 31 Iwadata K, Ito H, Katsumura S, Matsuyama N, Sato K, Yonemura I, *et al*. An autopsy case of bilateral tension pneumothorax after acupuncture. *Leg Med (Tokyo)* 2003;**5**:170–4.
- 32 White A. A cumulative review of the range and incidence of significant adverse events associated with acupuncture. *Acupunct Med* 2004;**22**:122–33.
- 33 Smith PF, Rauscher CR. Complication of acupuncture. *JAMA* 1974;**229**:1286.
- 34 Gee D. Fatal pneumothorax due to acupuncture. *BMJ* 1984;**288**:114.
- 35 Lee WM, Leung HB, Wong WC. Iatrogenic bilateral pneumothorax arising from acupuncture: a case report. *J Orthop Surg (Hong Kong)* 2005;**13**:300–2.
- 36 White A. Survey of adverse events following acupuncture (SAFA): a prospective study of 32,000 consultations. *Acupunct Med* 2001;**19**:84–92.
- 37 White A. A cumulative review of the range and incidence of significant adverse events associated with acupuncture. *Acupunct Med* 2006;**22**:122–33.
- 38 White A. The safety of acupuncture – evidence from the UK. *Acupunct Med* 2006;**24**(Suppl):53–7.
- 39 MacPherson H. A prospective survey of adverse events and treatment reactions following 34,000 consultations with professional acupuncturists. *Acupunct Med* 2001;**19**:93–102.
- 40 Yamashita H, Tsukayama H, White AR, Tanno Y, Sugishita C, Ernst E. Systematic review of adverse events following acupuncture: the Japanese literature. *Complement Ther Med* 2001;**9**:98–104.
- 41 Yamashita H, Tsukayama H, Tanno Y, Nishijo K. Adverse events in acupuncture and moxibustion treatment: a six-year survey at a national clinic in Japan. *J Altern Complement Med* 1999;**5**:229–36.
- 42 Umlauf R. Analysis of the main results of the activity of the acupuncture department of faculty hospital. *Acupunct Med* 1988;**5**:16–8.
- 43 Melchart D, Weidenhammer W, Streng A, Reitmayr S, Hoppe A, Ernst E, *et al*. Prospective investigation of adverse effects of acupuncture in 97 733 patients. *Arch Intern Med* 2004;**164**:104–5.
- 44 Witt CM, Pach D, Brinkhaus B, Wruck K, Tag B, Mank S, *et al*. Safety of acupuncture: results of a prospective observational study with 229,230 patients and introduction of a medical information and consent form. *Forsch Komplementmed* 2009;**16**:91–7.
- 45 Linde K, Streng A, Hoppe A, Jürgens S, Weidenhammer W, Melchart D. The programme for the evaluation of patient care with acupuncture (PEP-Ac) – a project sponsored by ten German social health insurance funds. *Acupunct Med* 2006;**24**(Suppl 25):25–32.
- 46 Weidenhammer W, Streng A, Linde K, Hoppe A, Melchart D. Acupuncture for chronic pain within the research program of 10 German Health Insurance Funds – basic results from an observational study. *Complement Ther Med* 2007;**15**:238–46.
- 47 Gee DJ. Unreviewed reports: fatal pneumothorax due to acupuncture. *Br Med J* 1984;**288**:114.
- 48 Peuker ET. Case report of tension pneumothorax related to acupuncture. *Acupunct Med* 2004;**22**:40–3.
- 49 von Riedenauer WB, Baker MK, Brewer RJ. Video-assisted thoroscopic removal of migratory acupuncture needle causing pneumothorax. *Chest* 2008;**131**:899–901.
- 50 Blanco M, Mor R, Fraticelli A, Breen DP, Dutau H. Distribution of breath sound images in patients with pneumothoraces compared to healthy subjects. Diagnostic yield of vibration response imaging technology. *Respiration* 2009;**77**:173–8.
- 51 Rhea JT, DeLuca SA, Greene RE. Determining the size of pneumothorax in the upright patient. *Radiology* 1982;**144**:733–6.

- 52 Botwin KP, Patel BC. Electromyographically guided trigger point injections in the cervicothoracic musculature of obese patients: a new and unreported technique. *Pain Physician* 2007; **10**:753–6.
- 53 Nelson LS, Hoffman RS. Intrathecal injection: unusual complication of trigger-point injection therapy. *Ann Emerg Med* 1998; **32**:506–8.
- 54 Richter JC, Kamlt W, O'Connor P. Pneumothorax and pleural emyema after acupuncture. *Intern Med J* 2008; **38**:678–80.
- 55 Shafer N. Iatrogenic pneumothorax. *N Y State J Med* 1972; **72**:2080–2.
- 56 Alvarez DJ, Rockwell PG. Trigger points: diagnosis and management. *Am Fam Physician* 2002; **65**:653–60.
- 57 Gray DJ. Variations in human scapulae. *Am J Phys Anthropol* 1942; **29**:57–72.
- 58 Pate D, Kursunoglu S, Resnick D, Resnik CS. Scapular foramina. *Skeletal Radiol* 1985; **14**:270–5.
- 59 Peuker E, Cummings M. Anatomy for the acupuncturist – facts & fiction 2: the chest, abdomen, and back. *Acupunct Med* 2003; **21**:72–9.
- 60 Schratte M, Bijak M, Nissel H, Gruber I, Schratte-Sehn AU. [The foramen sternale: a minor anomaly – great relevance]. *Rofo* 1997; **166**:69–71.
- 61 Stark P. Midline sternal foramen: CT demonstration. *J Comput Assist Tomogr* 1985; **9**:489–90.
- 62 Peuker ET, Gronemeyer D. Rare but serious complications of acupuncture: traumatic lesions. *Acupunct Med* 2001; **19**:103–8.
- 63 Campbell A. Point specificity of acupuncture in the light of recent clinical and imaging studies. *Acupunct Med* 2006; **24**:118–22.
- 64 Dhond RP, Kettner N, Napadow V. Do the neural correlates of acupuncture and placebo effects differ? *Pain* 2007; **128**:8–12.
- 65 Kim ES, Kang JY, Pyo CH, Rhee GW. Treatment of pneumothorax following acupuncture: is a closed thoracostomy necessary for a first choice of treatment modality? *J Altern Complement Med* 2009; **15**:183–6.
- 66 MacPherson H. Fatal and adverse events from acupuncture: allegation, evidence, and the implications. *J Altern Complement Med* 1999; **5**:47–56.